

Immunohistochemical detection of V600E BRAF mutation is a useful primary screening tool for malignant melanoma

GE Orchard^a, K Wojcik^a, W Rickaby^b, B Martin^b, K Semkova^b, F Shams^c and CM Stefanato^b

^aViapath Analytics, Dermatopathology Department, St John's Institute of Dermatology, St. Thomas' Hospital; ^bDermatopathology Department, St. John's Institute of Dermatology, St. Thomas' Hospital; ^cImperial College Healthcare NHS Trust, St. Mary's Hospital

ABSTRACT

Background: We compared the use of an immunohistochemical (IHC) method using a monoclonal antibody to BRAF V600E (which detects the main BRAF mutation) with existing DNA probe screening in tissue samples from 71 patients with malignant melanoma.

Materials and methods: Paraffin blocks were cut to provide consecutive slides for haematoxylin and eosin staining, and for known positive micro-array DNA control material. IHC was performed by the Optiview detection system. All slides were scored independently by the clinical lead and the laboratory lead using a positive/negative system.

Results: The DNA method found 26 samples to be positive, the IHC found 21 to be positive, giving a sensitivity value for IHC of 80.8%. However, all of the 45 samples found to be negative by DNA were also negative by IHC, giving a specificity of 100%. There were 66 instances of full agreement, giving a concordance of 93%. Together, these data give a kappa statistic of 0.843, indicating very good agreement.

Conclusion: The data reveal a very close link between the two methods, supporting the use of the V600E as a primary screen for BRAF mutations in malignant melanoma. Samples found to be negative by this method may be retested by the DNA probe method. IHC detection conserves patient DNA from tumour blocks as only one section is required to perform the assay. The V600E antibody method is considerably cheaper and faster than the DNA probe assay, with a turn-around time of 24–48 hours, enabling more rapid clinical management.

ARTICLE HISTORY

Received 30 January 2019
Accepted 13 February 2019

KEYWORDS

Malignant melanoma;
BRAF V600E;
immunohistochemistry

Introduction

In the majority of melanomas and solid tumours the RAS/RAF/MEK/ERK mitogen protein kinase pathway regulates the proliferation and survival of tumour cells. BRAF mutations are therefore integral to tumour activation [1,2]. These mutations have been found in varying percentages in a wide host of tumour types most notably melanoma, papillary thyroid carcinoma, colorectal cancers, ovarian cancers, non-small cell lung cancer and in 100% of patients with hairy cell leukaemia [3,4] to name but not exclusively list the key examples. Approximately 40–60% of cutaneous melanomas have the BRAF mutations [1,2]. In 90% of the cases, thymine is substituted with adenine at nucleotide 1799. This leads to valine (V) being substituted for by glutamate (E) at codon 600 (now referred to as V600E) [2]. The BRAF mutation activates the protein and the downstream Map Kinase (MAPK) signalling pathway, this promotes proliferation of tumour cells and subsequent spread. In melanoma patients under the age of 40 years >80% have the BRAF mutation and of these >85% are V600E [1,5]. The follow-up data on these mutations and subsequent patient outcomes clearly indicates that such mutations correlate with worsening prognosis not

only in melanoma but also colorectal cancers [6]. The use of potent inhibitors of V600 mutant BRAF such as PLX4032 (Vemurafenib) is a V600 mutant B-Raf enzyme inhibitor approved by the Food and Drug Administration (FDA) for the treatment of late-stage melanoma have made significant advancements in the treatment of metastatic melanoma, not only in terms of the rapid mode of action but also in prolonging patient survival rates. In a first phase of clinical study, PLX4032 Vemurafenib was able to reduce numbers of cancer cells in 11/16 patients of the cohort group with advanced melanoma. The treated group had a median increased survival time of 6 months over the control group [7]. Further phase II studies confirmed the activity of vemurafenib with an objective response rate of 53% and progression-free survival of 6–8 months in BRAF V600 mutant melanoma [8]. A third phase of study, in patients with a V600E mutation in B-Raf, 84% showed partial to complete regression. The median progression-free survival of the 680 randomised patients was 5.3 months [10]. Rapid screening for BRAF mutations is therefore highly desirable in the treatment of metastatic melanoma and particularly for those un-resectable forms of the disease [9,10]. Delays in the administration of

fast-acting targeted therapies can also have profound effects on patient quality of life and survival. Therefore, time and efficiency in screening for BRAF V600E mutations in melanoma patients can be highly beneficial in patient treatment regimes.

There are many DNA probe-based strategies for BRAF mutation screening. The most commonly employed include Sanger sequencing, pyrosequencing, real-time polymerase chain reaction (RT-PCR), co-amplification at low denaturation temperature PCR, locked nucleic acid PCR array analysis, allele-specific PCR, and high-resolution melting curve analysis (HRM) [1,2,11–15]. These DNA probe-based methods have differing degrees of sensitivity ranging from 80% to 99%. Similarly, they are expensive and often rely on the use of significant DNA material extracted from paraffin curls cut from patient blocks 1.

Here, we report the use of immunohistochemical (IHC) employing a monoclonal antibody to BRAF V600E in 71 malignant melanoma patients in comparison to the existing in house DNA probe pyrosequencing assay. The study was a retrospective blind trial, with two clear objectives. Firstly, to determine if the development of IHC methods for the BRAF mutations in melanoma patients can provide a rapid confirmation for the detection of the main V600E mutation and also be cost effective. Secondly, to determine the sensitivity and specificity of the V600E antibody for the detection of BRAF mutations in malignant melanoma patients.

Methods and materials

Seventy-one malignant melanoma patients who had previously been screened for BRAF mutations employing a DNA probe Sanger sequencing methodology within Viapath Analytics molecular diagnostic laboratories from the previous year, were selected from the archive diagnostic files. Of these the mean age was 69 years with an age range of 28–94 years. The male to female ratio was 37:34. Primary tumours were screened in ($n = 54$) 76% of cases with subcutaneous cases accounting for ($n = 17$) 24%. The staging according to tumour node metastasis (TNM) = pT1b and above in all cases in order to be selected for BRAF analysis (according to 7th edition AJCC).

All samples underwent BRAF DNA probe assessment using standard PCR and Sanger sequencing of exon 15 previously but results were not known until completion of the IHC assessments (blind trial).

Four micron-thick sections were cut from the paraffin blocks and Harris haematoxylin and eosin (H&E) preparations were made of all blocks evaluated (99) to assess tumour deposits post DNA probe testing and to ensure adequate material was left for the IHC assessments.

Four micron-thick sections were also cut for IHC and were all mounted on positive control Microarray HDx B-Raf V600E FFPE slides (Horizon Discovery, Catalogue ID-HD720). This enabled the test and control micro array to be assessed on the same slide.

The Roche Diagnostics BRAF V600E (VE-1) IHC monoclonal primary antibody (Ventana-Roche Diagnostics Catalogue ID 790-4855) was applied on all 71 cases. All IHC staining was performed on a Roche BenchMark Ultra fully automated immunostaining platform. The staining protocol followed Roche Diagnostic recommendations thus; antigen retrieval involved the use of CC1 at 72°C for 64 min. The pre-diluted ready to use Roche Diagnostics BRAF V600E (VE1) was applied to all slides from 50 tests per dispenser Roche antibody vial and incubated for 24 min at room temperature. The secondary linking and detection complex employed Roche Diagnostics Optiview DAB IHC Detection kit (760-700). All sections were then counterstain with Harris haematoxylin for 4 min to demonstrate the general morphology and nuclear detail of the test sections.

All slides were subsequently assessed in a blind trial fashion by both the clinical lead for St. John's Histopathology and the laboratory lead independently. Positive results were defined as exhibiting cytoplasmic expression within the identified melanoma tumour cells for BRAF V600E mutation as assessed under both $\times 20$ and $\times 40$ magnifications. The scoring was marked on scale of negative or positive with additional scores of (+), positive (++) , positive (+++) on all tumour cells graded on intensity of staining.

All IHC results were then tabulated and compared to the previously recorded results for Sanger sequencing for the DNA probe detection of BRAF mutations on the same patient material (Table 1). Sensitivity, specificity and a kappa value were calculated.

Results

Following review of the HE stained slides all 71 samples contained sufficient tumour content for BRAF V600E IHC analysis. Data from DNA probe screening found 26/71(36.6%) cases positive; 21/26 of these cases were also positive with IHC giving sensitivity 80.8% (Figures 1(a,b), 2(a,b), 3(a,b), 4(a,b)). The DNA probe screening found 45/71 (63.4%) cases negative; all cases were also negative with IHC (specificity = 100%). The concordance of IHC and DNA probe screening revealed 65/71 cases = 93%. Five cases were recorded as false negative (7%) but no cases were recorded as false positive by IHC. Of additional interest was the finding that one case which was positive for both BRAF mutation DNA probe and IHC screening, exhibited complete lack of staining for all the conventionally used IHC melanoma markers (anti-

Table 1. Characterisation of the samples

Type of tissue, age and sex of patients	IHC data	DNA probe data	Number of samples
Primary: 77 [60-86.5] years, 28M/25F	-	-	33
	-.*	+	4
	+	+	6
	++	+	10
	+++	+	1
Sub-lymph node: 67 [48-86], 2M/1F	-	-	2
	++	+	1
Sub-tissue: 67 [57-73], 4M/5F	-	-	6
	+	+	1
Sub-exc + lymph node: 53, F.	-	-	1
Metastatic: 71, M	-	-	1
Sub-nodules: 54 [34-85], 2M/1F	-	-	2
	-.*	+	1

Age data median [IQR]. *False negative.

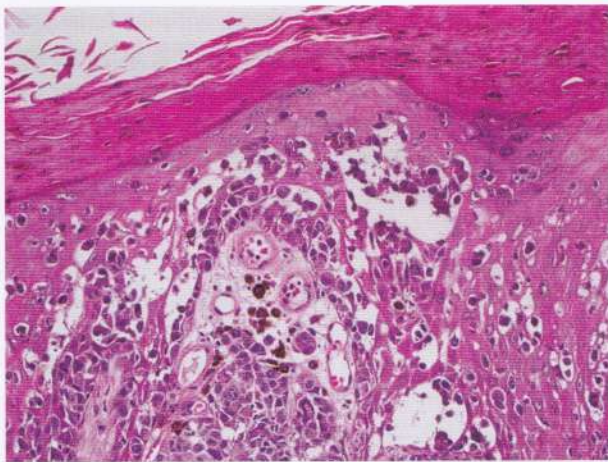


Figure 1a. H&E staining showing invasive epithelioid malignant melanoma tumour cells in a case of acral lentiginous malignant melanoma Mag $\times 20$.

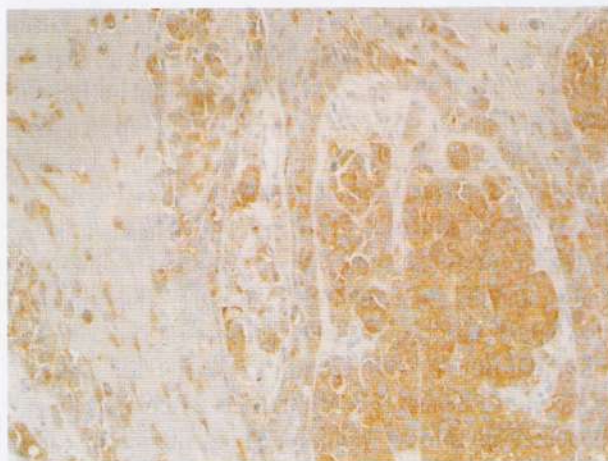


Figure 1b. BRAF (V600E VE-1) labelling of the same case as in (a), showing cytoplasmic expression of BRAF in all tumour cells seen Mag $\times 20$.

S100 protein, Melan A and HMB 45) (Figure 5(a-e)). The significance for this is unclear as the cohort is just one case, but it suggests markers of melanocyte activation (anti-Melan A and anti-HMB 45) may not be closely related to the BRAF mutation pathway.

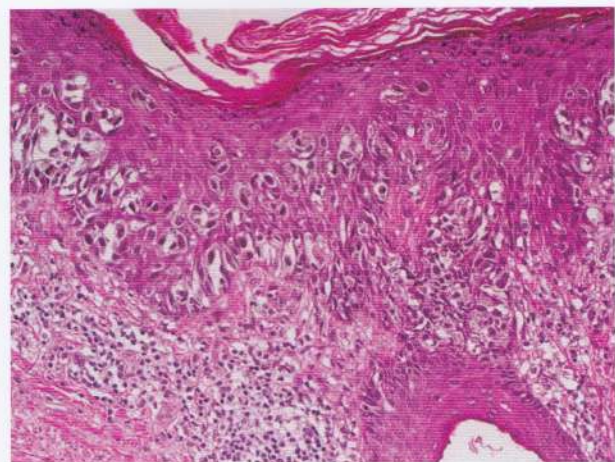


Figure 2a. H&E staining showing pagetoid spread of tumour cells within a superficial spreading malignant melanoma Mag $\times 20$.

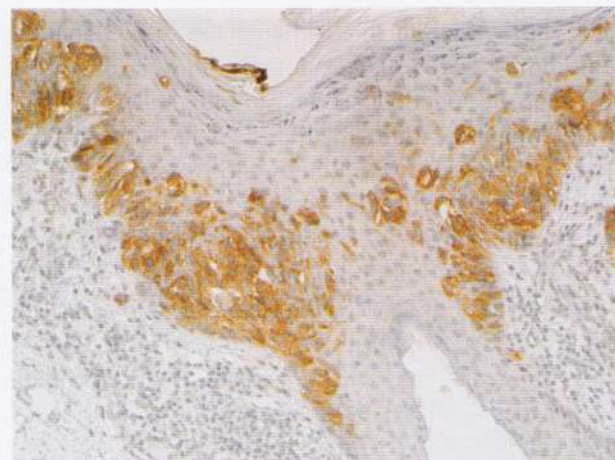


Figure 2b. BRAF (V600E VE-1) labelling of the same case as in (a) showing universal cytoplasmic expression of BRAF in all tumour cells within the epidermal compartment Mag $\times 20$.

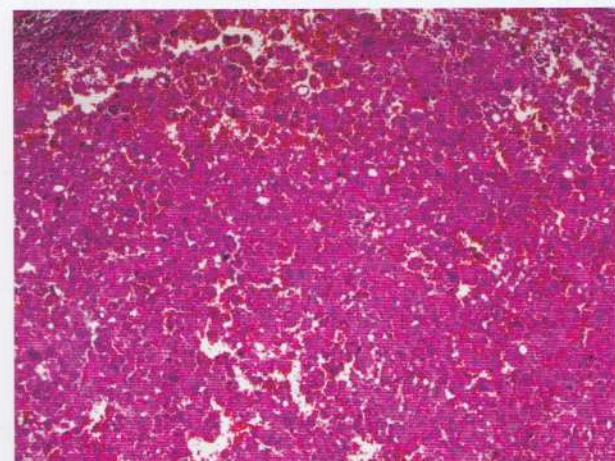


Figure 3a. H&E staining showing metastatic malignant in a lymph node with extensive malignant melanoma tumour deposits Mag $\times 10$.

Discussion

The overall data suggest the following. Primary IHC screening for BRAF V600E reveals some negative cases. Ideally all negative cases should then be sent for DNA

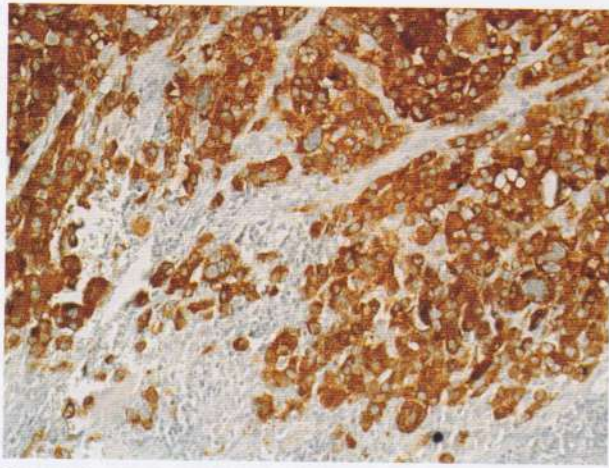


Figure 3b. BRAF (V600 VE-1) labelling of the same case as in (a) showing universal cytoplasmic expression of BRAF in all tumour cells. Note the lack of any background staining Mag $\times 20$.

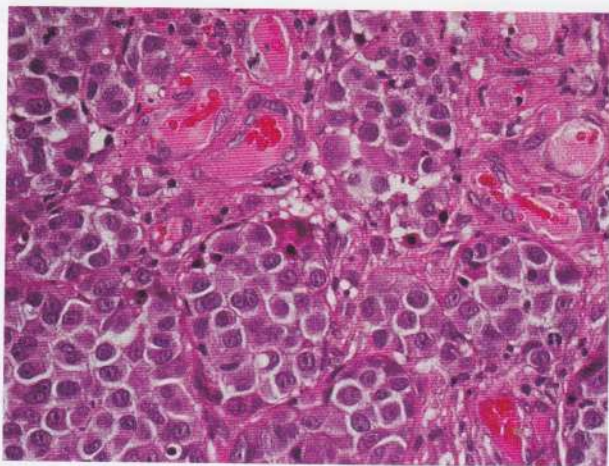


Figure 4a. H&E staining of a tumour cell nest composed of predominantly epithelioid tumour cells in a case of nodular melanoma Mag $\times 40$.

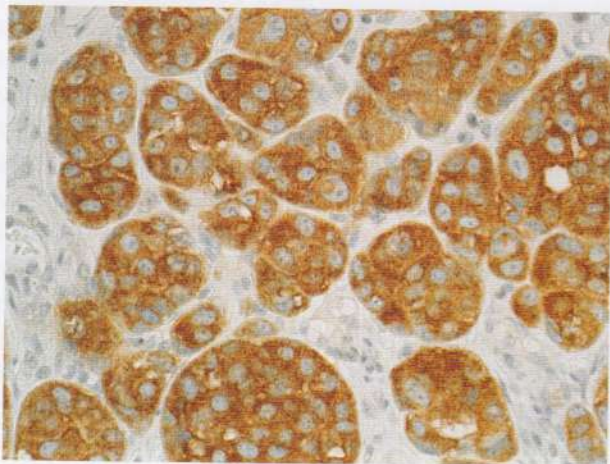


Figure 4b. BRAF (V600E VE-1) labelling of the same case as in (a) showing universal positive cytoplasmic staining of all tumour cells with complete absence of any nonspecific background staining Mag $\times 40$.

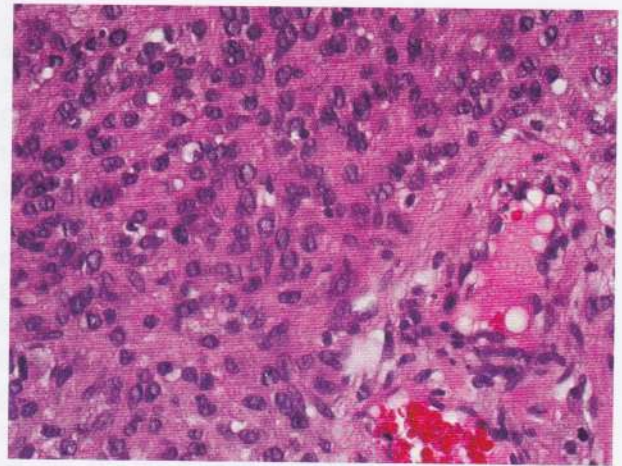


Figure 5a. (a) H&E of a metastatic melanoma deposit showing predominantly small round tumour cells Mag $\times 20$.

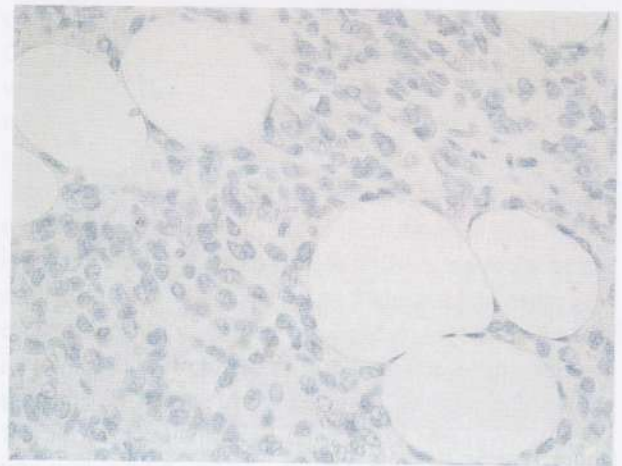


Figure 5b. (b) Negative staining with HMB 45 in the same case as in (a) Mag $\times 40$.

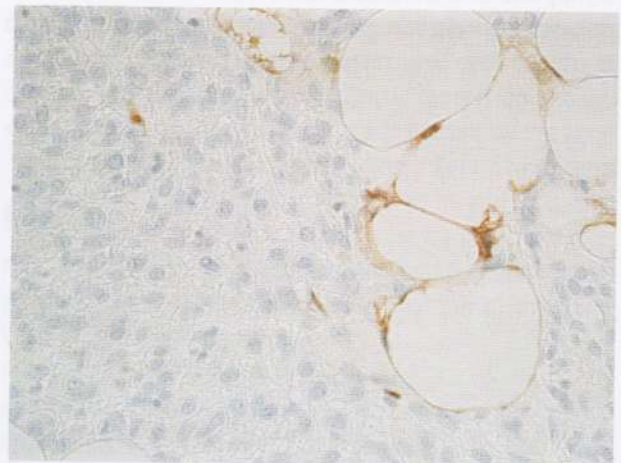


Figure 5c. (c) Negative S100 staining of tumour cells but positive labelling of adipocytes in the same case as (a,b).

probe screening. Accepting this procedure would mean that all the five negative IHC cases in this study would be re-assessed for a DNA probe assay and therefore would

be defined as positive (26/26) cases. This result in terms of sensitivity produces a concordance between the two methods of 100%.

The data reveal high sensitivity and specificity for the IHC detection of BRAF V600E mutations in

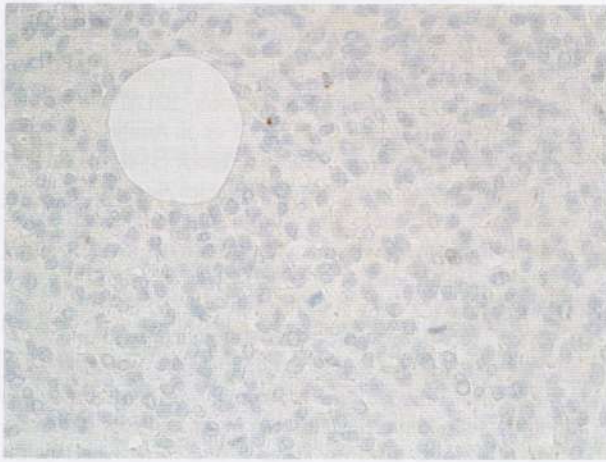


Figure 5d. (d) Negative Melan A staining of tumour cells within the same case as in (a-c) Mag $\times 40$.

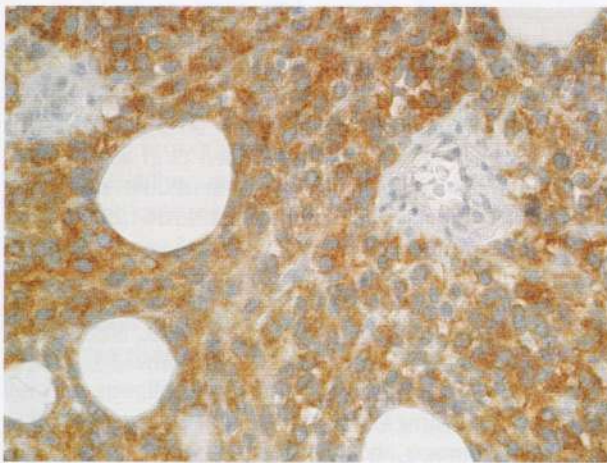


Figure 5e. (e) Positive cytoplasmic expression of BRAF V600E (VE-1) of all tumour cells in the same case as in (a-d) Mag $\times 40$.

Table 2. BRAF summary.

Factors to be considered	BRAF IHC test	BRAF DNA probe test
Speed	1-2 days	4-7 days plus
Cost	Cheaper, around half the price	More expensive, almost double the price
Tissue preservation	Only 1 section per slide required	Multiple tissue curls required (15 curls at around 10 μm thickness)
Localisation	Enables to specifically locate mutated tumour cells within a tissue	n/a
Sensitivity	80.8%	100%
Specificity	100%	100%

metastatic melanoma. Assessing the two techniques together there are clear advantages and disadvantages for the use of either DNA probe-based or IHC-based screening. The time of the IHC assay is just 1-2 days and is 4-7 days for conventional DNA probe screening currently. This gives clear advantages in terms of speed and optimal response times for IHC BRAF V600E screening.

IHC requires one section (4 microns) while DNA probe screening requires multiple tissue curls amounting to (60-70 microns) of material. IHC is therefore preserving of patient tissue. The current study also demonstrated uniformity of IHC V600E staining of all tumour cells when positive in any given case. It also allows precise location of antigenic expression within tumour cells. Recent single cell RT-PCR studies have suggested that the majority of naevi and primary and metastatic melanomas contain both wild-type and mutant BRAF cells. Since assessments of polyclonality in the process of studies into melanomagenesis is key to future potential treatment regimes, more studies to determine V600E single-cell IHC staining in conjunction with single-cell RT-PCR seems a logical progressive step 1 [16,17].

Cost per test for IHC cheaper compared to DNA probe screening approximately, half the price. Thus, suggesting the test can be used more widely as a primary quick response cost effective screen. Subsequently, patient management is improved by providing faster drug administration in all positive detected cases.

This study concurs with previous publications which confirm that IHC detection for V600E (VE-1) BRAF mutations is both highly sensitive and specific. A previous study also suggested that following DNA probe screening review and repeats of five discordant cases from IHC and DNA probe screening comparisons from an original study cohort of 100 melanoma patients revealed that only two cases remained discordant after repeating the DNA mutational analysis [1]. This suggests that the IHC V600E (VE-1) detection was more sensitive for the mutation than had traditional sequencing techniques. It may also reflect the continuing improvements in the sensitivity of existing polymer-based IHC detection systems over conventional Avidin-biotin detection systems. The impact of fixation methods on the ability for both DNA probe and IHC systems to work optimally was difficult to evaluate as in some cases the paraffin-embedded block material was received from external referral sources, this must impart some differences as fixation will have varied and not be standardised for all cases.

BRAF inhibitors have also been shown to show clinical activity in melanoma patients with mutations other than V600E, for example V600K. This means that the identification of other BRAF mutations will still be required. However, proportionally these cases are in the minority and screening for V600E using IHC will allow rapid optimal patient treatment for the vast majority of BRAF mutant melanoma patients. Studies to determine if the effective, combined use of IHC and DNA probe detection for BRAF V600E mutations enables

improved patient quality of life and survival outcomes, compared to just DNA probe screening on its own remains to be fully confirmed. Ideally, it requires a large controlled clinical trial cohort study. Application of BRAF V600E IHC in the assessment of other solid tumours such as colorectal, thyroid and lung will need further assessment in order to establish baseline data of expression within these tumours.

This work represents an advance in biomedical science because it shows that the detection of BRAF mutations relating to V600E can be performed efficiently and accurately using IHC detection as well as DNA probe analysis.

Summary table

What is known about this subject:

- Mutation BRAF V600E is a significant mutation that is implicated in the metastatic spread of malignant melanoma.
- Fast and efficient primary screening for the BRAF V600E using immunohistochemical screening, may improve patient management of malignant melanoma patients.

What this study adds:

- Provides evidence for the application of IHC assessment for the primary screening of melanoma patients for BRAF V600E.
- Provides evidence of the close concordance between IHC and DNA probe-based methods for the detection of BRAF V600E.


Disclosure statement


No potential conflict of interest was reported by the authors.


Funding

This work was supported by the NA [NA].

ORCID

GE Orchard  <http://orcid.org/0000-0002-4757-0022>

F Shams  <http://orcid.org/0000-0003-2457-7771>

CM Stefanato  <http://orcid.org/0000-0003-0526-3443>

References

- [1] Long G, Wilmott JS, Capper D, et al. Immunohistochemistry is highly sensitive and specific for the detection of V600E BRAF mutation in melanoma. *Am J Surg Pathol*. 2013;37:61–65.
- [2] Schirosi L, Strippoli S, Gaudio F, et al. Is immunohistochemistry of BRAF V600E useful as a screening tool and during progression disease of melanoma patients? *BMC Cancer*. 2016;16:905 p1–11.
- [3] Arkenau HT, Kefford R, Long GV. Targeting BRAF for patients with melanoma. *Br J Cancer*. 2011;104:392–398.
- [4] Schindler G, Capper D, Mayer J, et al. Analysis of BRAF V600E mutation in 1,320 nervous system tumors reveals high mutation frequencies in pleomorphic xanthoastrocytoma, ganglioglioma and extra-cerebellar pilocytic astrocytoma. *Acta Neuropathol*. 2011;121:397–405.
- [5] Long GV, Menzies AM, Nagrial AM, et al. Prognostic and clinicopathologic associations of oncogenic BRAF in metastatic melanoma. *J Clin Oncol*. 2011;29:1239–1246.
- [6] Roth AD, Tejpar S, Delorenzi M, et al. Prognostic role of KRAS and BRAF in stage II and III resected colon cancer: results of the translational study on the PETACC-3, EORTC 40993, SAKK 60-00 trial. *J Clin Oncol*. 2010;28:466–474.
- [7] Flaherty K. Advances in drug development BRAF validation in melanoma. *Clin Adv Hematol Oncol*. 2010;8:31–34.
- [8] Sosman JA, Kim BA, Schuchter L, et al. Survival in BRAF V600 – mutant advanced melanoma treated with vemurafenib. *N Engl J Med*. 2012;366:707–714.
- [9] Chapman PB, Hauschild A, Robert C, et al. Improved survival with vemurafenib in melanoma with BRAF V600E mutation. *N Engl J Med*. 2011;364:2507–2516.
- [10] Kim A, Cohen MS. The discovery of vemurafenib for the treatment of BRAF- mutated metastatic melanoma. *Expert Opin Drug Discov*. 2016;11:907–916.
- [11] Pinzani P, Santucci C, Mancini I, et al. BRAF V600E detection in melanoma is highly improved by COLD-PCR. *Clin Chim Acta*. 2011;412:901–905.
- [12] Busby K, Morris A. Detection of BRAF mutations in colorectal tumours and peritoneal washings using a mismatch ligation assay. *J Clin Pathol*. 2005;58:372–375.
- [13] Oldenburg RP, Liu MS, Kolodney MS. Selective amplification of rare mutations using locked nucleic acid oligonucleotides that competitively inhibit primer binding to wild-type molecular. *J Invest Dermatol*. 2007;128:398–402.
- [14] Stark M, Hayward N. Genome-wide loss of heterozygosity and copy number analysis in melanoma using high-density single-nucleotide polymorphism arrays. *Cancer Res*. 2007;67:2632–2642.
- [15] Jarry A, Masson D, Cassagnau E, et al. Real-time allele-specific amplification for sensitive detection of the BRAF mutation V600E. *Mol Cell Probes*. 2004;18:349–352.
- [16] Lin J, Takata M, Murata H, et al. Polyclonality of BRAF mutations in acquired melanocytic nevi. *J Natl Cancer Inst*. 2009;101:1423–1427.
- [17] Lin J, Goto Y, Murata H, et al. Polyclonality of BRAF mutations in primary melanoma and the selection of mutant alleles during progression. *Br J Cancer*. 2011;104:464–468.